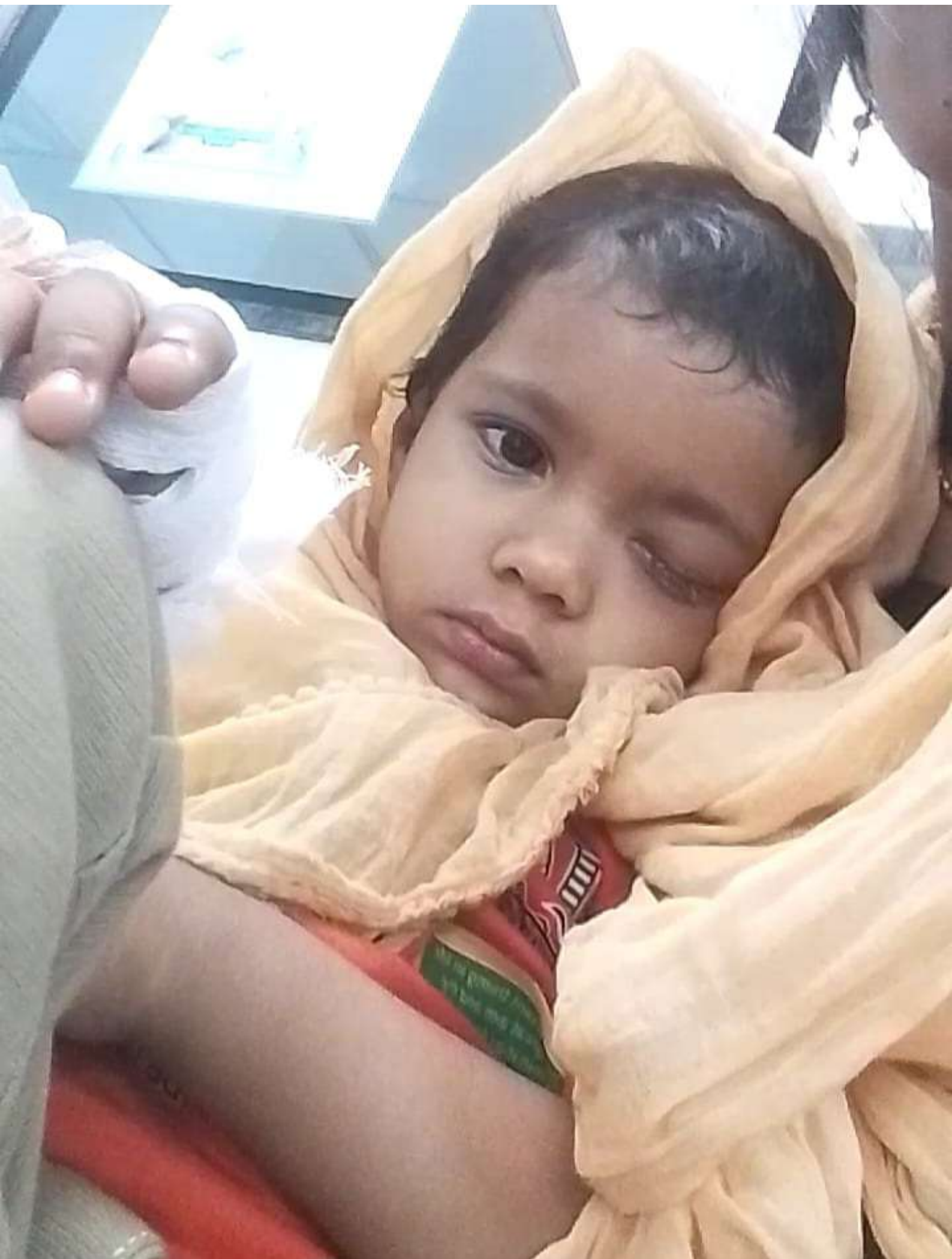



ब. रो. वि. कार्ड

O.P.D. Card

डा. राजेन्द्र प्र
अ. भा. आयु.

Dr. Rajendra P
A.I.I.M.S., New

यू.एच.आई.डी.
UHID No.

रोगी व
Name of t



UHID: 108662073
ABHA:
Dept No: 20250050120043

MAHIM 1

D/O AM. RJEET YADAV
2Y 5M 2D / F
CHANDARPUR BARWA CHHAWANI,
KUSHIN/ GAR, UTTAR PRADESH,
Mob: 842 90128783 General Rs 0
Follow U: Patient

दृष्टि

अनुभाग व दिन
Section and Day

कमरा / Room: 32
Unit-V
RFC OPD

Dr. Rachna Meel

TUE, FRI
मंगल, शुक्र



Registration time:
10/04/2026 10:01:13 AM

कमरा नंबर
Cabin No.

ता
ress

दिनांक
DATE

निदान
DIAGNOSIS

(R) EORB III B

उपचार Treatment

10 APR 2026

Post 6 cycle of chemo cycle.

Enucleated (R) globe

Shows ON extensive post lamellar
infiltration
resected margins free of
tumour

Smith
~~OT~~

UA date

Continue 6 more # of
chemo.

RT registration Dr Sauri IRE
(Thursday)

कृपया इस कार्ड को सुरक्षित रखें तथा अस्पताल में दिखाने के समय हर वक्त साथ लायें।

Kindly keep this Card safely and bring it on your follow-up visits.

1. धूम्रपान निषेध 2. कूड़ा कर्कट केवल कूड़ेदान में ही डालें 3. थूकिये नहीं

1. No Smoking

2. Use Dustbin

3. No Spitting



DEPARTMENT OF RADIODIAGNOSIS & INTERVENTIONAL RADIOLOGY
ALL INDIA INSTITUTE OF MEDICAL SCIENCES (AIIMS)
NEW DELHI

Patient Name:	MAHIMA MAHIMA	Gender/Age:	F/2 y
UHID:	108662073	Exam Date:	04/02/2026 1:37PM
OPD / Ward:	R. P. Centre (Eye Centre)	Modality:	MR
Procedure:	MRI SCAN Main	Room:	NMR MAIN

History: C/O right side retinoblastoma, On chemotherapy, To assess response.

IMAGING PARAMETERS

Brain

Axial: T1 post contrast

ORBIT

Axial: T2 & T1 post contrast

Coronal: T2 & T1 post contrast

Sag oblique T2 and T1 C+

Findings;

Right globe:

There is vitreous hemorrhage with retinal detachment in right globe and an irregular nodular soft tissue (T2 hypointense) lesion with a cystic component noted in the left lateral aspect in vitreous chamber measuring 8.5 x 11.8 x 5.6 mm

The enhancing component measures approximately 6.7 x 4.5 x 5.6 mm s/o residual tumour.

Mild enhancement seen in peri optic region behind the nerve head. ? PLONI
However there is no significant optic nerve enhancement

Left globe:

Left globe is normal in outline and signal intensity.

Left optic nerve is normal in bulk and signal intensity.

No e/o enlargement, abnormal signal intensity or abnormal enhancement

Left extraocular muscles are normal in bulk and signal intensity.

Retroorbital fat is normal. No intraorbital mass lesion is seen.

Brain:

Both the cerebral hemispheres show normal MR morphology, signal intensity and grey-white matter differentiation.

Both lateral ventricles and third ventricle is normal in size.



डा. बी. आर. अम्बेडकर संस्थान रोटरी कैंसर अस्पताल
Dr. B.R. Ambedkar Institute Rotary Cancer Hospital
अ भा आ सं अस्पताल / A.I.I.M.S. HOSPITAL

OPR-6

DR. B.R.A. IRCH, AIIMS, NEW DELHI

IRCH No. 355628

Reg. Date-02/04/2026

Clinic Paediatric Medical Oncology Clinic

Clinic No. 2025/8452

Deptt. MEDICAL ONCOLOGY

General



नाम

UHID-108662073

Name MAHIMA

D/O- AMARJEET YADAV

Phone No. 8429928783

Address CHANDARPUR BARWA CHHAWANI, KUSHINAGAR, UTTAR PRADESH, Pin:274306, INDIA

Paid Online

Patient Department

PROHIBITED IN HOSPITAL PREMISES

वि. पंजीकृत सं. / O.P.D. Regn. No.

RT-137966

आयु
Age

जन्म तिथि / Date of Birth

↓ Prof. Abhitagni Biswas.

निदान / Diagnosis

(R) Eye EORB - III A → S/P 6 OVEC → S/P (R) eye

दिनांक / Date

08.05.2026

उपचार / Treatment

Enucleation + 1^o implant
S/P 1 OVEC (Post op)

C/w Prof. Dr. A. Biswas.

PLAN: (R) orbital PORT (↓GA).
40 Gy/20 # / 4 weeks.

Adv 1) DFRT 10/06/26 → R - (28)
(8:30 AM)

2) Anaesthesia clearance

R - (60) IRCH

(CBC / LFT / KFT / CXR / ECG)

3) CBC / KFT / LFT.

4) Review in RO-OPD on 09/06/26.

Tuesday (R-4) 9 AM

Review PAC [anaesthesia clearance]

* fresh blood reports.

अंगदान-जीवन का बहुमूल्य उपहार / ORGAN DONATION - A GIFT OF LIFE

O.R.B.O., AIIMS, 26588360, 26593444, www.orbo.org Helpline 1060 (24 hrs service)

बाहर से आने वाले रोगियों के लिए धर्मशाला की सुविधा उपलब्ध है/Dharamshala facility is available for outstation patients

Aleera → 9559823232



डा. बी. आर. अम्बेडकर संस्थान रोटरी कैंसर अस्पताल
Dr. B.R. Ambedkar Rotary Cancer Hospital

OPR-6

अ.भा.आ.सं. अ
बहिरंग रोगी वि
अस्पताल के अन्दर धुम्रपान म

DR. B.R.A. IRCH, AIIMS, NEW DELHI
IRCH No. 355628
Clinic Paediatric Medical Oncology Clinic
Deptt. MEDICAL ONCOLOGY
General
नाम
Name MAHIMA
D/O- AMARJEET YADAV
Phone No. 8429928783
Address CHANDARPUR BARWA CHHAWANI, KUSHINAGAR, UTTAR
Reg. Date-02/04/2026
Clinic No. 2025/8452
UHIP-108662073
Sex/Age F/2Y
Room 6 (Shift Afternoon)

एकक/Unit Prjy SB/Dr DP
विभाग/Dept. MO

नाम/ Name

पिता/पुत्र/पत्नी/
F/S/W/H/I

Birth

11/5/26

निदान/ Diagnosis

(R) FORB; s/p Emulation (24/26)

दिनांक/ Date

उपचार/ Treatment

(file N/A)

CBC/UT/MT
(N)

Dose C# 8 VEC

- RT admimi 9/6/26?

plan

wt = 12kg

Inj Emunt 2mg + Dexa 2mg IV stat

Inj VCR 0.5 mg slow IVP

Inj CARBOPLATIN 200 mg / 100 ml 5% D over 2hrs

Inj ETOPOSIDE 120 mg / 300 ml 5% D over 1hr

Post: - Syp Emunt (5ml/2mg) 5ml 3x/day x 5 days

Tab Dexa (4mg) 1/2 BD

N/V 01/06/26 T CBC, URT, MT

wt- 11.7kg

(D1)

(Days)



Date: 11/5/26
Dr. G. SHRAVANI REDDY
Senior Resident
DM Pediatric Oncology
AIIMS, New Delhi-110029

रेलवे आरक्षण फार्म जारी लिखित

Rly. Concession

अंगदान-जीवन का बहुमूल्य उपहार / ORGAN DONATION-A GIFT OF LIFE

O.R.B.O., AIIMS, 26588360, 26593444, www.orbo.org Helpline-1060 (24 hrs.service)

बाहर से आने वाले रोगियों के लिए धर्मशाला की सुविधा उपलब्ध है / Dharamshala facility is available for outstation patients

Dr. B. R. AMBEDKAR INSTITUTE ROTARY CANCER HOSPITAL
ALL INDIA INSTITUTE OF MEDICAL SCIENCES NEW DELHI

DAYCARE DRUGS ADMINISTERED

Date: 11-05-2026

Indoor RegNo.: 0	UHID: 108662073	IRCH No.: 355628	Ward: DayCare
Patient Name: MAHIMA MAHIMA	Age: 2	Sex: Female	Consultant Name: DR. SAMEER BAKHSHI

Hb:	Platelets:	TLC:	ANC:	Urea:
Creatinine:	Bilirubin:	SGOT(AST):	SGPT(AST):	Alk Ph:

Diagnosis	Protocol:	Cycle/Day:
Height:	Weight:	BSA: 0 m ²

PREMEDICATION GIVEN

Inj Ondansetron 2 mg

Inj Dexamethasone 2 mg

CHEMOTHERAPY / IMMUNOTHERAPY GIVEN

SNo	Drug Name	Drug Other	Final Dose	Unit	Soln	Duration
1	Other	inj vcr	0.5mg			Slow IV Push
2	Other	inj Carboplatin	200mg	100 ml	5%D	2 hrs
3	Other	inj Etoposide(VP-16)	120mg	250 ml	5%D	1 hr

SUPPORTIVE CARE GIVEN

Signature of Nurse



Dr. KAMAL GARG
Senior Resident Physician
Department of Medical Oncology
BRAIRCH & AIIMS, New Delhi



भारत सरकार
Government of India



बाल आधार

Aadhaar no. issued: 01/05/2026



Mahima

Date of Birth/DOB: 20/10/2023

Female/ FEMALE

यह आधार 5 वर्ष की उम्र तक ही वैध है

आधार पहचान का प्रमाण है, नागरिकता या जन्मतिथि का नहीं ।
इसका उपयोग सत्यापन (ऑनलाइन प्रमाणीकरण, या क्यूआर कोड/
ऑफ़लाइन एक्सएमएल की स्कैनिंग) के साथ किया जाना चाहिए ।

**Aadhaar is proof of identity, not of citizenship
or date of birth.** It should be used with verification (online
authentication, or scanning of QR code / offline XML).

5526 7605 8841

मेरा आधार, मेरी पहचान




भारतीय विशिष्ट पहचान प्राधिकरण
Unique Identification Authority of India



Details as on: 09/05/2026

Address:
C/O: Rabina Yadav, Chandarpur barwa, Chandarpur,
PO: Laxmiganj, DIST: Kushinagar,
Uttar Pradesh - 274306



5526 7605 8841

VID : 9130 8333 1291 5964

1947

help@uidai.gov.in

www.uidai.gov.in



भारत सरकार

Government of India



Issue Date: 12/01/2015



रबीना यादव
Rabina Yadav
जन्म तिथि/DOB: 20/08/2001
महिला/ FEMALE

5199 4638 6944

VID : 9147 4230 9933 5614

मेरा **आधार**, मेरी पहचान



भारतीय विशिष्ट पहचान प्राधिकरण

Unique Identification Authority of India



पता:

पता: अमरजीत यादव, चंदरपुर बरवा, चंदरपुर, कुशीनगर,
उत्तर प्रदेश - 274306

Address:

C/O: Amarjeet Yadav, Chandarpur Barwa,
Chandarpur, Kushinagar,
Uttar Pradesh - 274306



5199 4638 6944

VID : 9147 4230 9933 5614



1947



help@uidai.gov.in



www.uidai.gov.in